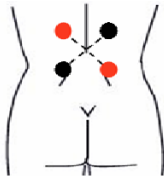
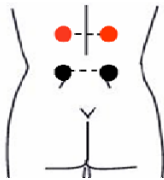


TruWave TENS Suggested Electrode Placement



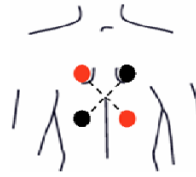
IFC Modality
Place the electrodes with the **RED** and **BLACK** ends of the leadwires according to pattern depicted on figure to the left.



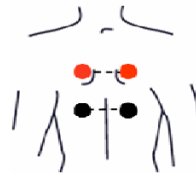TENS / NMES Modality
Place the electrodes with the **RED** and **BLACK** ends of the leadwires according to pattern depicted on figure to the left.

Using both channels and crisscrossing the electrodes is optional when using the TENS or NMES modality.

Lumbar Back



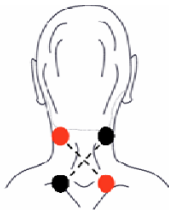
IFC Modality
Place the electrodes with the **RED** and **BLACK** ends of the leadwires according to pattern depicted on figure to the left.



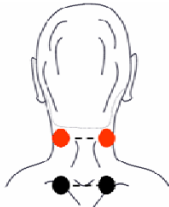
TENS / NMES Modality
Place the electrodes with the **RED** and **BLACK** ends of the leadwires according to pattern depicted on figure to the left.

Using both channels and crisscrossing the electrodes is optional when using the TENS or NMES modality.

Thoracic Back



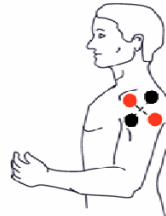IFC Modality
Place the electrodes with the **RED** and **BLACK** ends of the leadwires according to pattern depicted on figure to the left.



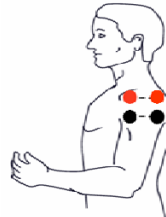TENS / NMES Modality
Place the electrodes with the **RED** and **BLACK** ends of the leadwires according to pattern depicted on figure to the left.

Using both channels and crisscrossing the electrodes is optional when using the TENS or NMES modality.

Cervical / Neck



IFC Modality
Place the electrodes with the **RED** and **BLACK** ends of the leadwires according to pattern depicted on figure to the left.



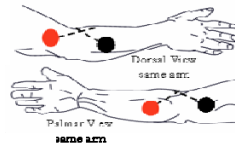
TENS / NMES Modality
Place the electrodes with the **RED** and **BLACK** ends of the leadwires according to pattern depicted on figure to the left.

Using both channels and crisscrossing the electrodes is optional when using the TENS or NMES modality.

Shoulder

IFC Modality

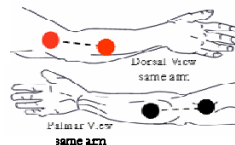
Place the electrodes with the **RED** and **BLACK** ends of the leadwires according to pattern depicted on figure below.



TENS Modality

Place the electrodes with the **RED** and **BLACK** ends of the leadwires according to pattern depicted on figure below.

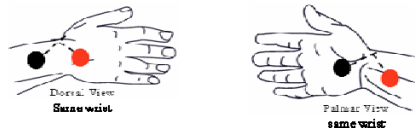
Using both channels and crisscrossing the electrodes is optional when using the TENS or NMES modality.



Elbow

IFC Modality

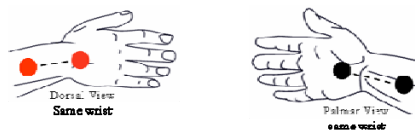
Place the electrodes with the **RED** and **BLACK** ends of the leadwires according to pattern depicted on figure below.



TENS Modality

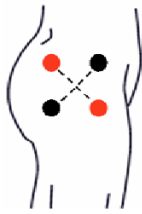Place the electrodes with the **RED** and **BLACK** ends of the leadwires according to pattern depicted on figure below.

Using both channels and crisscrossing the electrodes is optional when using the TENS or NMES modality.

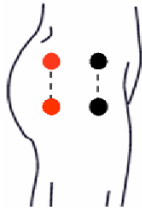


Hand

TruWave TENS Suggested Electrode Placement



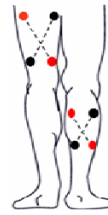
IFC Modality
Place the electrodes with the **RED** and **BLACK** ends of the leadwires according to pattern depicted on figure to the left.



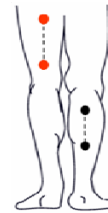
TENS / NMES Modality
Place the electrodes with the **RED** and **BLACK** ends of the leadwires according to pattern depicted on figure to the left.

Using both channels and crisscrossing the electrodes is optional when using the TENS or NMES modality.

Hip



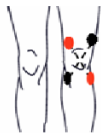IFC Modality
Place the electrodes with the **RED** and **BLACK** ends of the leadwires according to pattern depicted on figure to the left.



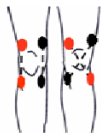TENS / NMES Modality
Place the electrodes with the **RED** and **BLACK** ends of the leadwires according to pattern depicted on figure to the left.

Using both channels and crisscrossing the electrodes is optional when using the TENS or NMES modality.

Back of Leg



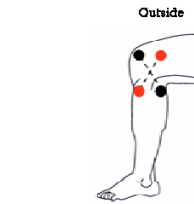
IFC Modality
Place the electrodes with the **RED** and **BLACK** ends of the leadwires according to pattern depicted on figure to the left.



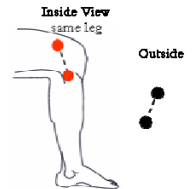
TENS / NMES Modality
Place the electrodes with the **RED** and **BLACK** ends of the leadwires according to pattern depicted on figure to the left.

Using both channels and crisscrossing the electrodes is optional when using the TENS or NMES modality.

Anterior Knee



IFC Modality
Place the electrodes with the **RED** and **BLACK** ends of the leadwires according to pattern depicted on figure to the left.



TENS / NMES Modality
Place the electrodes with the **RED** and **BLACK** ends of the leadwires according to pattern depicted on figure to the left.

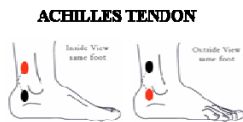Using both channels and crisscrossing the electrodes is optional when using the TENS or NMES modality.

Lateral / Medial Knee

IFC Modality
Place the electrodes with the **RED** and **BLACK** ends of the leadwires according to pattern depicted on figure below.

TENS / NMES Modality
Place the electrodes with the **RED** and **BLACK** ends of the leadwires according to pattern depicted on figure below.

Crisscrossing the electrodes is optional when using the TENS or NMES modality.



ANKLE

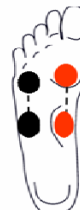

ANKLE

Ankle



IFC Modality
Place the electrodes with the **RED** and **BLACK** ends of the leadwires according to pattern depicted on figure to the left.

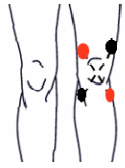

TENS / NMES Modality
Place the electrodes with the **RED** and **BLACK** ends of the leadwires according to pattern depicted on figure to the left.

Using both channels and crisscrossing the electrodes is optional when using the TENS or NMES modality.

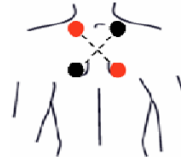Foot

TruWave TENS Suggested Electrode Placement



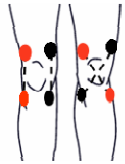IFC Modality

Place the electrodes with the **RED** and **BLACK** ends of the leadwires according to pattern depicted on figure to the left.



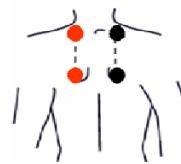
IFC Modality

Place the electrodes with the **RED** and **BLACK** ends of the leadwires according to pattern depicted on figure to the left.



TENS Modality

Place the electrodes with the **RED** and **BLACK** ends of the leadwires according to pattern depicted on figure to the left. *Criscrossing the electrodes is optional when using TENS waveform.*



NMES Modality

Place the electrodes with the **RED** and **BLACK** ends of the leadwires according to pattern depicted on figure to the left.

Post-Operative Knee

Muscle Spasm

Note:

The most important aspect of TENS electrode placement is to position them so that the current passes through the painful area and along the nerves leading away from the pain.

These are suggested settings. All settings and placement of electrodes should be instructed by a medical practitioner.